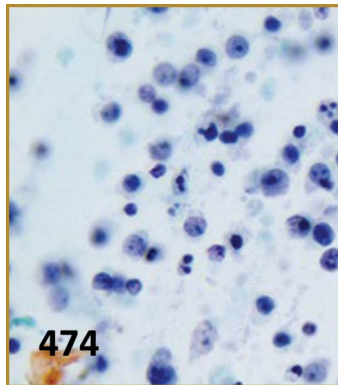


Table of Contents



From the Editor's Desk..... 465

Full Cases



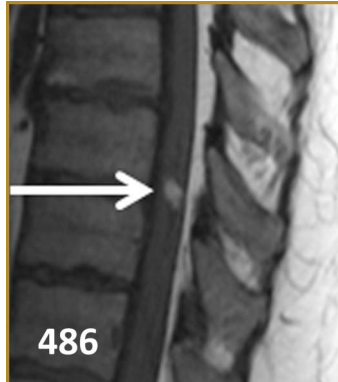
Capgras-like visual decomposition in Lewy body dementia with therapeutic response to donepezil 467

Karen Reimers, Natalie Emmert, Harshit Shah, Ralph H.B. Benedict, and Kinga Szigeti



NMDA receptor encephalitis causing reversible caudate changes on MRI and PET imaging..... 470

William O. Tobin, Edythe A. Strand, Heather M. Clark, Val J. Lowe, Carrie E. Robertson, and Sean J. Pittock



Central neurogenic hyperventilation: A sign of CNS lymphoma 474

Alexander Pantelyat, Steven L. Galetta, and Amy Pruitt

Acute changes in ventricular volume during treatment for hepatic and renal failure..... 478

Eric M. Liotta, Rebecca M. Bauer, Michael D. Berman, James C. Guth, Matthew B. Maas, Andrew M. Naidech, and Neil F. Rosenberg

Periodic alternating gaze deviation and nystagmus in posterior reversible encephalopathy syndrome..... 482

Devin D. Mackay, Rodrigo Zepeda Garcia, Steven L. Galetta, and Sashank Prasad

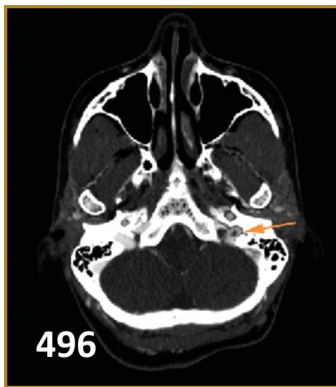


Spinal dural arteriovenous fistula with intramedullary cord hemorrhage: Diagnostic challenges 486

Kristen A. Schmidt, Josephine F. Huang, David F. Black, Timothy J. Kaufmann, Giuseppe Lanzino, and Neeraj Kumar

An exotic cause of encephalopathy in a patient with chronic kidney disease..... 490

Iris Yung, Howan Leung, Jack Ng, Terry Ma, Kai Ming Chow, Vincent Mok, and Lawrence Wong



Autoimmune encephalitis mimicking Creutzfeldt-Jakob disease 493

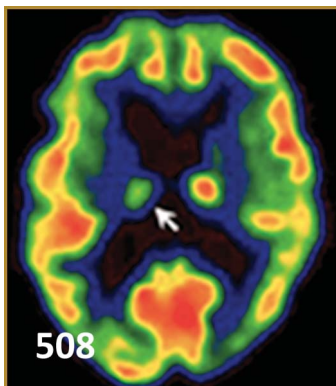
Olga P. Fermo, Izlem Izbudak, Raoul Sutter, Arun Venkatesan, Peter W. Kaplan, and John C. Probasco

Atypical presentation of venous infarct: Developmental venous anomaly thrombosis propagating from clot in dural venous sinus 496

Chris Bent, Peter Shen, Roy Poblete, Brian Dahlin, Paul Lee, Anna Nidecker, and Matthew Bobinski

Management of levodopa-induced jig-like gait disorder with pallidal stimulation 499

Joseph M. Ferrara, David J. Houghton, Colleen Knoop, and Michael C. Park



Long segment spinal cord involvement as the clinical manifestation of sarcoidosis 502

Jamie L. Adams and Steven L. Galetta

Superficial greater petrosal neuropathy 505


Sashank Prasad, Thomas C. Lee, E. Antonio Chiocca, and Joshua P. Klein

Primary Whipple disease of the CNS presenting with chorea and dystonia: A video case report ... 508

Jose-Alberto Palma, Maria R. Luquin, Mario Riverol, Pablo Irimia, Miriam Fernandez-Alonso, Javier Tejada, and Eduardo Martinez-Vila

Hearing loss in Wernicke encephalopathy 511

Melissa A. Walker, Rodrigo Zepeda, Henrietta A. Afari, and Adam B. Cohen



Sensory neuronopathy associated with tumor necrosis factor inhibitor therapy 516

Julius Birnbaum

Hashimoto encephalopathy with angiographic CNS vasculitis 519

Ameer Al-Wafai, Mervat Wahba, Vinodh T. Doss, and Lucas Elijevich

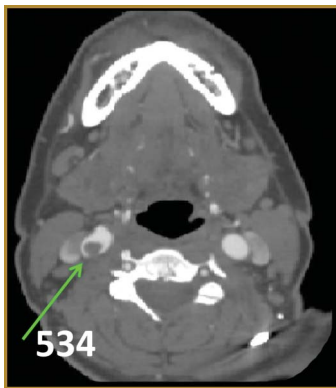


Image Cases

Alternating ictal and postictal nystagmus 522

Salman Bhai, Athar N. Malik, Khamidulla Bakhadirov, and Sashank Prasad

Pontine infarction responsible for wall-eyed bilateral internuclear ophthalmoplegia syndrome 524

Thibaud Mathis, François Ducray, Caroline Tilikete, Alain Vighetto, and Damien Biotti

Eight-and-a-half syndrome 526

Alexandra Duffy, Peter Yi Shen, Piero Verro, Anna E. Nidecker, and Matthew Chow

MRI spot sign 528

Jeremy K. Cutsforth-Gregory, David F. Black, E. Matthew Hoffman, Sudhir V. Datar, and Eelco F. Wijdicks

SMART syndrome: Stroke-like migraine attack after radiation therapy 530

Nancy Wang and Sashank Prasad

Acute peripheral vestibulopathy in a cocaine addict: Cracking the vestibular nucleus 532

Anteneh M. Feyissa, Todd Masel, and Stephen P. Busby

The disappearing thrombus: An uncommon cause of ischemic stroke 534

David P. Lerner and Carmelo Graffagnino

Symptomatic free-floating carotid thrombus extending to the skull base 536

Barend Mees, Domenic Robinson, Gary Fell, and Peter Chu

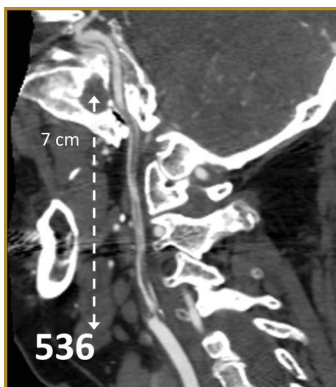
Posterior spinal cord infarctions due to neurosyphilis 538

Olivier Bill, Renaud A. Du Pasquier, and Patrik Michel

Hypotheses and Musings

Interval progression of idiopathic hypertrophic pachymeningitis 541

Nitin K. Sethi



Publication Information

Neurology® is a registered trademark of the American Academy of Neurology (registration valid in the United States). *Neurology*® Clinical Practice (ISSN 2163-0402) is published 6 times per year for the American Academy of Neurology, 201 Chicago Avenue, Minneapolis, MN 55415, by Wolters Kluwer, 16522 Hunters Green Parkway, Hagerstown, MD 21740-2116. Business offices are located at Two Commerce Square, 2001 Market St., Philadelphia, PA 19103. Production offices are located at 351 West Camden Street, Baltimore, MD 21201-2436. © 2014 American Academy of Neurology.

Annual Subscription Rates: United States: \$341.00 Individual, \$658.00 Institution, \$116.00 In-training. Outside the United States: \$390.00 Individual, \$740.00 Institution, \$116.00 In-training. Single copy rate \$124.00. All prices include a handling charge. Subscriptions outside of North America must add \$4.00 for airfreight delivery. United States residents of AL, CO, DC, FL, GA, HI, IA, ID, IN, KS, KY, LA, MD, MO, ND, NM, NV, PR, RI, SC, SD, UT, VT, WA, WV add state sales tax. The GST tax of 7% must be added to all orders shipped to Canada (Wolters Kluwer's GST Identification #895524239, Publications Mail Agreement #1119672). Subscription prices outside the United States must be prepaid. Prices subject to change without notice. Visit us online at www.lww.com.

Individual and in-training subscription rates include print and access to the online version. Institutional online subscriptions can be purchased through Ovid by contacting the publisher. Please contact Wolters Kluwer, 16522 Hunters Green Parkway, Hagerstown, MD 21740-2116; phone 800-638-3030 (outside the United States 301-223-2300); fax 301-223-2400.

Address for non-member subscription information, orders, or change of address: Wolters Kluwer, P.O. Box 1580, Hagerstown, MD 21741-1580; phone 800-638-3030 (outside the United States 301-223-2300; fax 301-223-2400). In Japan, contact LWW Igaku-Shoin Ltd., 3-23-14 Hongo, Bunkyo-ku, Tokyo 113-0033; phone 81-3-5689-5400; fax 81-3-5689-5402. In Bangladesh, India, Nepal, Sri Lanka, and Pakistan, contact Globe Publications Pvt. B-13 3rd Floor, A Block, Shopping Complex, Naraina Vihar, Ring Road, New Delhi, 110028; phone 91-11-579-3211; fax 91-11-579-8876.

Address for member subscription information, orders, or change of address: *Neurology: Clinical Practice* is a benefit of membership to the American Academy of Neurology. To become a member or provide a change of address, please contact the American Academy of Neurology, 201 Chicago Avenue, Minneapolis, MN 55415 (or call 612-928-6000). For all other membership inquiries, contact Wolters Kluwer Customer Service Department, P.O. Box 1580, Hagerstown, MD 21741-1580; phone 800-638-3030 (outside the United States 301-223-2300); fax 301-223-2400; e-mail memberservice@lww.com. Please indicate training status and name of institution. Institutional rates apply to libraries, hospitals, corporations, and partnerships of three or more individuals. Prices are subject to change without notice. Subscriptions will begin with currently available issue unless otherwise requested. Copies will be replaced without charge if the publisher receives a request within 90 days of the mailing date.

Copyright and Permission Information: No portion(s) of the work(s) may be reproduced without written consent from Wolters Kluwer. Permission to reproduce copies of articles for non-commercial and commercial use may be obtained from Rightslink which can be found at the article level under Request Permission. More information can be found on <http://www.lww.com/Home/opencms?id=JournalPermission>.

Licensing, Translation Rights & Licensing queries: Please contact Silvia Serra, Director of Rights, Licensing, Permissions, Wolters Kluwer (Medical Research) Ltd, 250 Waterloo Road, London SE1 8RD, UK, tel: +44 (0)207 981 0600; Silvia.Serra@wolterskluwer.com.

Disclaimer: Opinions expressed by the authors and advertisers are not necessarily those of the American Academy of Neurology, its affiliates, or of the Publisher. The American Academy of Neurology, its affiliates, and the Publisher disclaim any liability to any party for the accuracy, completeness, efficacy, or availability of the material contained in this publication (including drug dosages) or for any damages arising out of the use or non-use of any of the material contained in this publication.

Advertising Sales Representatives: Wolters Kluwer, 333 Seventh Avenue, New York, NY 10001. Contacts: Eileen Henry-Hubert, tel: 732-778-2261, fax: 973-215-2485, Eileen.Henry-Hubert@wolterskluwer.com and Valentin Torres, tel: 646-674-6354, cell: 646-628-4530, fax: 917-677-8420, Valentin.Torres@wolterskluwer.com. In Europe: Avia Potashnik, Wolters Kluwer, 250 Waterloo Road, London SE1 8RD, UK, tel: +44 (0) 207 981 0722, fax: 44 7919 397 933, Avia.Potashnik@wolterskluwer.com.

Careers & Events: Ryan Magee, Wolters Kluwer, Two Commerce Square, 2001 Market Street, Philadelphia, PA 19103, tel: 215-521-8804, fax: 215-521-8801, Ryan.Magee@wolterskluwer.com.

Reprints: Michele Livewell, Wolters Kluwer, Two Commerce Square, 2001 Market Street, Philadelphia, PA 19103, tel: 215-521-8941, Michele.Livewell@wolterskluwer.com, reprintsolutions@wolterskluwer.com.

Special Projects: US & Canada: Alan Moore, Wolters Kluwer, Two Commerce Square, 2001 Market Street, Philadelphia, PA 19103, tel: 215-521-8638, Alan.Moore@wolterskluwer.com. International: Silvia Serra, Wolters Kluwer, 250 Waterloo Road, London SE1 8RD, UK, tel: +44 (0)207 981 0600, Silvia.Serra@wolterskluwer.com.

Postmaster: Send address changes to *Neurology: Clinical Practice*, P.O. Box 1550, Hagerstown, MD 21740.

Neurology® Clinical Practice

4 (6)

Neurol Clin Pract 2014;4:465-543

This information is current as of January 1, 2014

Updated Information & Services	including high resolution figures, can be found at: http://cp.neurology.org/content/4/6.citation.full.html
Permissions & Licensing	Information about reproducing this article in parts (figures,tables) or in its entirety can be found online at: http://cp.neurology.org/misc/about.xhtml#permissions
Reprints	Information about ordering reprints can be found online: http://cp.neurology.org/misc/addir.xhtml#reprintsus

Neurol Clin Pract is an official journal of the American Academy of Neurology. Published continuously since 2011, it is now a bimonthly with 6 issues per year. Copyright . All rights reserved. Print ISSN: 2163-0402. Online ISSN: 2163-0933.

